

# James Homer Wright (1869–1928)

ROBERT H. YOUNG AND ROBERT E. LEE

THE ARRIVAL OF Dr. James Homer Wright as the first full-time pathologist was a seminal event in the history of pathology at the Massachusetts General Hospital (MGH), since it represented the founding of what is now known as the Pathology Service. Dr. Wright was a remarkably talented investigator who made an impressive number of original contributions and left a rich legacy.

James Homer Wright (figures 4.1 and 4.2) was born on April 8, 1869, in Pittsburgh, the oldest of five children of Homer Wright and Sara L. Gray. As Dr. Wright's first and second names are almost always given when he is referred to in the literature, a brief note on the manner in which he was addressed is merited. As best we can tell, all who were close enough to him not to address him as Dr. Wright referred to him as J. Homer or Jim; his niece addressed him as Uncle Homer. Dr. Wright's father had a business that made decorative glass tableware. In 1885 Wright was sent to Faribault, Minnesota, to receive his secondary education at a school that was sponsored by the Episcopal Church and named in honor of a benefactor, Dr. George Cheyne Shattuck, Hersey Professor of the Theory and Practice of Physic at Harvard Medical School (HMS), who also endowed a Chair of Pathological Anatomy at HMS. After three years in Minnesota, Wright entered Johns Hopkins University and graduated with honors in 1890. He then attended the

University of Maryland School of Medicine, receiving his degree in the spring of 1892. During his Hopkins years he worked in pathology under Drs. William H. Welch and William Councilman, and his first paper, published in 1891, was based on this work. He received a gold medal for his overall performance and a first prize in surgery. His initial appointment was as a Thomas Scott Fellow at the University of Pennsylvania's Department of Hygiene under Dr. John Shaw Billings, who suggested that Wright investigate the bacteriology of the Philadelphia river waters.

In 1893, Dr. Wright was invited to join the HMS Pathology Department, as Assistant in Pathology, by Dr. William Councilman, who had moved from Baltimore to Boston the previous year to be the first full-time pathologist to occupy the Shattuck Chair of Pathological Anatomy at HMS. Dr. Wright began working in the Sears Laboratory of Boston City Hospital (then affiliated with HMS) in July 1893. In 1894 he conducted a study of the pathology of 82 patients with diphtheria, including autopsy data on 14 of them, and the paper that resulted was published in the *Boston Medical and Surgical Journal* (now the *New England Journal of Medicine*).

In the mid-1890s Dr. Wright began a significant and long-lasting collaboration with Dr. Frank Burr Mallory. Dr. Mallory (who was the father of Dr. Wright's successor at the MGH, Tracy Burr Mallory; chapter 6) had earlier joined




Figure 4.1 James Homer Wright, as a young man

Dr. Councilman at Boston City Hospital. In 1898 Mallory and Wright published the first edition of a textbook entitled *Pathological Technique* (figure 4.3), which became the standard text for hospital laboratories for more than four decades. The first edition had almost 400 pages and 105 illustrations. The initial part was devoted to the autopsy and included detailed coverage of the manner of external and internal examination of the body; the second part dealt with bacteriology, and the third with histological methods.

Dr. Wright was appointed Associate Pathologist and Director of the newly established Clinico-Pathological Laboratory at the MGH on March 13, 1896; he was only 26 years old. The laboratory, located on Allen Street, was officially

opened on October 16, 1896. Wright was very pleased with the new laboratory, especially since it was a great improvement over the former facilities, which the hospital Trustees had likened to a “little den.”

Dr. Wright’s main associate during his long tenure (1896–1926), helping him with much of the routine autopsy and microbiological work in the laboratory, was Dr. Oscar Richardson. In addition, Drs. William F. Whitney and Harry F. Hartwell participated in surgical pathology. Many eminent clinicians also spent time in the Pathology Laboratory during the Wright era. Dr. Joseph Aub, the endocrinologist, credited Wright with pioneering the tradition of laboratory investigation by clinicians at MGH. Sixteen benches were set aside for staff members to do research, for which they were charged about \$25 a year. Some of the eminent clinicians who spent time in the laboratory and were influenced by Wright were Dr. Robert B. Greenough, a surgeon who wrote one of the first papers grading breast cancer during those years and chaired the committee that ultimately became the Commission on Cancer of the American College of Surgeons; Dr. Elliott P. Joslin, after whom the renowned Joslin Clinic for diabetes is named; Dr. George R. Minot of pernicious anemia fame, who acknowledged Wright near the beginning of his Nobel Prize acceptance speech of 1934 (“about 1910 the late Dr. James Homer Wright taught me to appreciate the character of the abnormality of the bone marrow in pernicious anemia”); and Dr. Richard C. Cabot, founder of the Case Records of the Massachusetts General Hospital (chapter 24).

Dr. Wright’s publications during his early years at MGH continued to show his talents in medical microbiology, including reports on meningococcal meningitis, Madura foot, *Leishmania tropica*, and actinomycosis. His paper on actinomycosis won him the Gross Prize in 1905, and he contributed the chapter on actinomycosis for the first edition of Sir William Osler’s *Modern Medicine*.



Figure 4.2 James Homer Wright, during his later years

He also wrote a chapter on other infections for that work. During his early years in Boston, Dr. Wright also authored a twice-yearly review of progress in pathology in the *Boston Medical and Surgical Journal*. This was a multipage summary of published research with a detailed literature review. The series had been initiated by Dr. Councilman in 1893, but Dr. Wright took it over in 1895 and was responsible for it until 1901. The topics included a wide spectrum of disease, but Wright's interest in infectious diseases is apparent from the large number of papers reviewed in that area. Ironically, Dr. Wright was stricken with typhoid fever in 1897. It is unclear how long he was absent from work, but documentation exists that he compensated Dr. Richardson for acting in his place while he was ill.

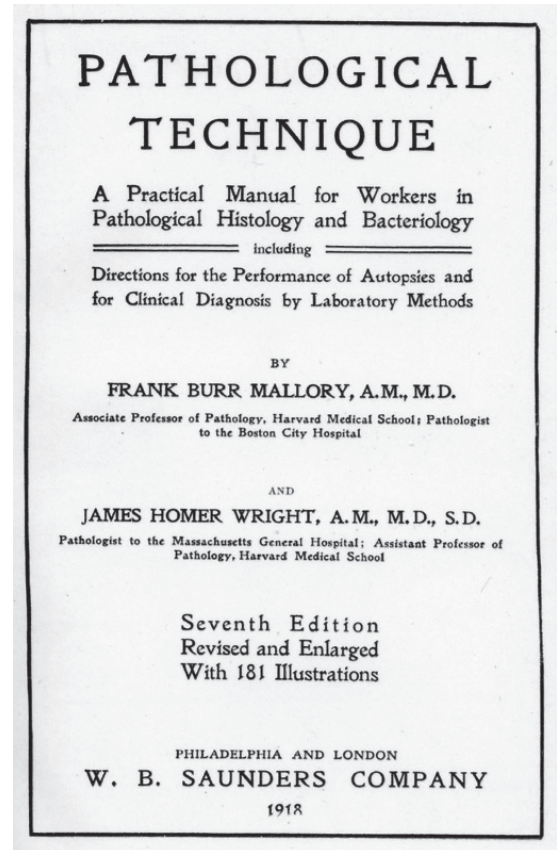


Figure 4.3 Title page of the 7th edition of *Pathological Technique*, the final edition worked on by both Mallory and Wright

Dr. Wright had a major interest in the preparation and examination of tissues, as evidenced by his book with Dr. Mallory. One example was his 1901 contribution on the frozen section technique, in which he advocated fixing tissue by briefly boiling it in formalin before cutting and staining. No additional major change in frozen section technique came about until years later, with the advent of the cryostat. In their book Mallory and Wright helped popularize use of the rotary microtome by pathologists. When Francis Blake, the inventor of the first rotating microtome, spoke about it to the Boston Society of Medical Sciences in 1899, his talk was followed by a demonstration by Wright. In his remarks Blake noted that the microtome had been in constant use at the MGH Pathology Laboratory for nearly



a year and “its success, in this regard, is largely due to the ingenuity and the skillful manipulation of our co-member Dr. James H. Wright. Indeed, a substantial improvement, in the matter of bracing the knife, has been made at his suggestion.” As the quality of the illustrations in his publications readily demonstrate, Dr. Wright was well aware that it was crucial to depict what was seen under the microscope vividly in illustrations, and he worked closely with his technician, Louis S. Brown, to develop photomicrography (chapter 3).

Another significant contribution to the technical aspects of pathology, which has immortalized his name, was the development of the Wright stain. He published his work (a modification of the Leishman stain) in an article in the *Journal of Medical Research* (now the *American Journal of Pathology*) in January 1902. Work on the stain had been preceded two years earlier by one of four other major contributions. The first of these, published in 1900 in a Festschrift in the *Johns Hopkins Hospital Reports* honoring Dr. William Welch and in the *Boston Medical and Surgical Journal*, described the cell of origin of multiple myeloma (figure 4.4). Although its clinical features had been described 25 years previously, the cell of origin was not known. Wright autopsied a 54-year-old male patient of Dr. Reginald Fitz. The patient suffered from symptoms of spinal cord compression and had tumors involving the skull, sternum, and ribs, as well as proteinuria. In Wright’s article, eight photomicrographs showed that the tumor cells, which were confined to bones, resembled plasma cells.

In 1906, although methods were available for recognizing and counting blood platelets, nothing was known about their origin. Dr. Wright studied the megakaryocytes of the cat, which are very large, in sections of bone marrow, spleen, and lung that had been prepared using the Wright stain. His first paper showing that platelets were derived from fragments of megakaryocytes was published in the *Boston Medical and Surgical Journal* in 1906 (figure 4.5). In August

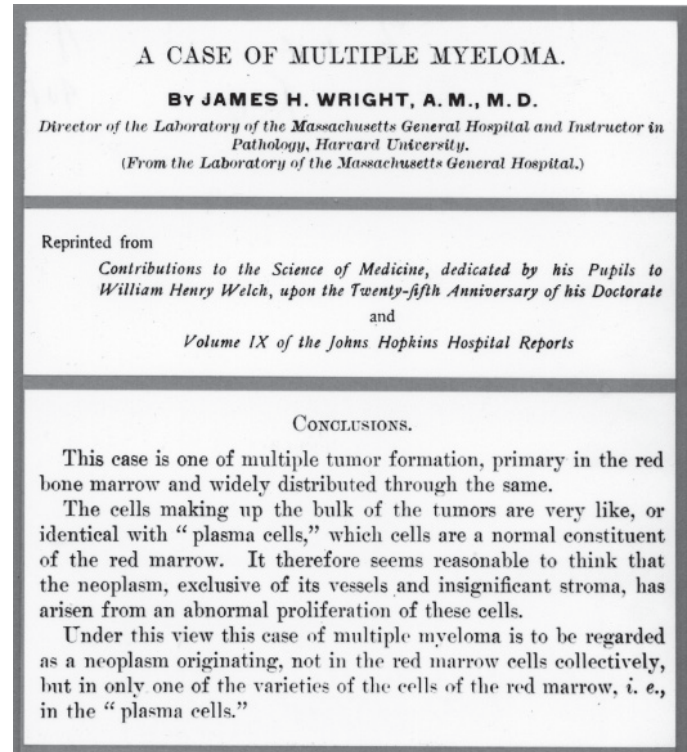


Figure 4.4 Selected portions of classic paper on multiple myeloma

1910 a more detailed paper appeared in the *Journal of Morphology*. The 21 illustrations, published in color, were made from his own watercolor drawings. Their quality is striking, and in 1998 they were picked to grace a book cover (see notes at the end of this chapter). Evidence for the megakaryocytic origin of platelets lay in the facts that both megakaryocytes and platelets had identical-appearing cytoplasm; both had amoeboid motion; megakaryocytes lose cytoplasm as they age; megakaryocytes and platelets appear in developing mammals simultaneously; and in diseases in which platelets are either increased or decreased, megakaryocytes vary similarly.

In 1910 Dr. Wright published his observations on 12 cases of a tumor composed of small, round cells that he believed were derived from primitive elements of the nervous system (figure 4.6). He compared the fibrils associated with the tumor cells and their ball-like arrangement with the

appearance of the developing sympathetic nervous system, and so designated this tumor a neuroblastoma. Authors reporting neuroblastomas subsequently paid tribute to Wright's observations by linking him with the rosettes he described (figure 4.7), although they have come down in history associated with both his middle and last names, Homer Wright rosettes.

The last of the four outstanding publications of his MGH years was his 1909 paper (with Dr. Oscar Richardson) in which they demonstrated spirochetes within the damaged aortic wall of five patients; the cause of the disease was assumed to be syphilis. In each of these cases a Levaditi stain revealed spirochetes. Until that time, spirochetes had been suspected but not identified as the agents responsible for the disease—except for two reports in the German literature.

Dr. Wright's accomplishments resulted in a number of honors, including honorary degrees of doctor of science from Harvard University (1905) and the University of Maryland (1907). After 1910, however, there was a decline in his academic output for reasons that are not entirely clear, although a schism clearly developed between him and senior hospital clinicians, and this may have contributed. He was asked to resign as Chief of Pathology in September 1925, but he continued in a consultant capacity until his death in 1928.

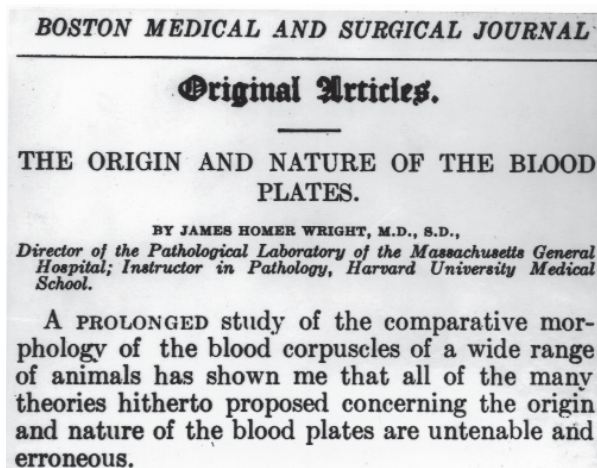


Figure 4.5 Seminal paper on origin of platelets

**NEUROCYTOMA OR NEUROBLASTOMA, A KIND OF TUMOR NOT GENERALLY RECOGNIZED.<sup>1</sup>**

BY JAMES HOMER WRIGHT, M.D., S.D.

*Director of the Pathological Laboratory, Massachusetts General Hospital, and Assistant Professor of Pathology, Harvard Medical School, Boston.*

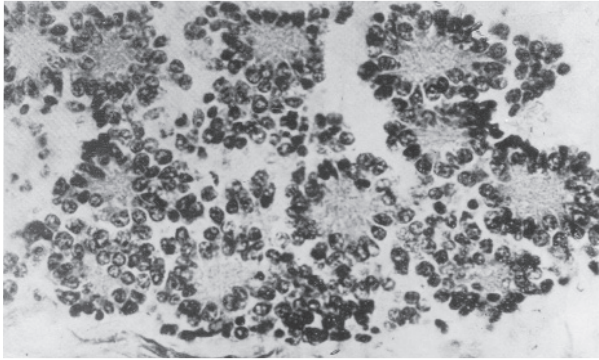
PLATES XLIV-XLVI.

The object of this paper is to call attention to a group of tumors, the nature of which has hitherto escaped general recognition, and to point out their distinguishing characteristics. These tumors are rich in cells which may vary much in size and shape. They may be pervaded by connective tissue by which the cells are arranged in more or less definite alveoli. Blood vessels accompanied by connective tissue are also present. The essential cells of the tumor are considered to be more or less undifferentiated nerve cells or neurocytes or neuroblasts, and hence the names neurocytoma and neuroblastoma. They are considered to be neurocytes or neuroblasts for the following reasons:

Figure 4.6 Title page of paper on neuroblastoma

Dr. Wright was a reserved person who did not participate much in professional societies or hospital committees—as best as can be judged from the available records. He also appears to have found lecturing students stressful. One close friend, Dr. Arlie Bock, referred to his “gruff exterior” but balanced this by noting that when entertaining in his home he was “wonderfully warm and charming.” The eminent cardiologist Dr. Paul Dudley White noted, “Dr. Wright was a formidable and rather forbidding man until you got to know him as I did. We became warm friends and he taught me much about microscopy and gross pathology in both of which he was an important pioneer.” Dr. White went on to express regret that he was unable to dissuade Wright from smoking cigarettes and also made reference to his use of alcohol (which may well have increased during the period of grief and loneliness that followed the death of his wife; see below). In a letter to Dr. Wright's brother following Dr. Wright's death, Dr. Arlie Bock made the following remarks: “J. Homer as everyone called him contributed much more than his share to the glory of the hospital and to his profession and of course has deeply engraved his name in the science of medicine. It will never be forgotten as long as our archives last. He was the only man on the teaching force of the Harvard Medical School





*Figure 4.7 Illustrations of structures now known as Homer Wright rosettes from Dr. Wright's paper on neuroblastoma*

who succeeded in awakening in me a real feeling about medicine and I will always regard him from a different angle than any man I know for this reason.”

Despite his “gruff exterior,” Wright clearly had a softer side. On Christmas Day 1901 he married a Norwegian singer, Aagot Lunde of Christiania (now Oslo), Norway. She was from a large family, having eight sisters and two brothers. It is likely Dr. Wright met her in late 1899, when she was on a tour that included appearances in Boston and Worcester. One evening Dr. Wright heard his future wife singing at a recital and, never having met her, anonymously sent flowers to her after the performance, something repeated daily until the gesture led to their meeting. The Wrights (figure 4.8) frequently returned to Aagot Wright's homeland, and her sisters periodically visited her in America. She died in 1923, almost certainly, on the basis of the recorded signs and symptoms, of ovarian carcinoma. During her final months she was looked after by, among others, Dr. Wright's sister Mary, who came from Pittsburgh, and by a Catherine Scully, who touchingly wrote: “Dr. Wright would join Mrs. Wright in her room and read to her from 7:00 until 9 o'clock. He never missed a night.” Scully also indicated the effect Aagot Wright's illness had on him when she noted, “He was always depressed if he had a day in the laboratory with positive cancer findings

and hoped to see the day when cancer would be cured.” Scully recorded Dr. Wright and his sister visiting Norway after Aagot Wright's death and taking her family some personal items. Scully also commented on Dr. Wright's speaking Norwegian fluently.

Dr. Wright died suddenly of pneumonia (contracted on his way home from Pittsburgh, where he had spent Christmas 1927) in the Phillips House of the MGH on January 3, 1928. He and his wife had no children; they were buried in Newton Center Cemetery, in the town of Newton, where they had lived most of their married life.

## NOTES

This is a revised version of a manuscript that was published in the *American Journal of Surgical Pathology* (26:88–96, 2002) authored by Robert E. Lee, Robert H. Young, and Benjamin Castleman. Work on that project had begun in the early 1970s, and on May 4, 1979, a presentation



*Figure 4.8 James Homer Wright and his wife Aagot*

was made at the fifty-second Annual Meeting of the American Association for the History of Medicine. The 2002 essay contains a list of all Dr. Wright's publications.

Dr. Wright's watercolor illustrations from his work on the origin of platelets appear on the cover of Murphy MJ, Kuter, DH, eds., "Thrombopoietin from molecule to medicine," *Stem Cells* 16 (suppl 2), 1998.

#### SELECTED PUBLICATIONS OF JAMES HOMER WRIGHT

1. Wright JH. Studies in the pathology of diphtheria. *Boston Med & Surg J* 131, no. 14:329–335, and no. 15:357–362, 1894.
2. Councilman FB, Mallory FB, Wright JH. Cerebro-spinal meningitis and its relation to other forms of meningitis. *J Bost Soc Med Sci* 2:53–57, 1897.
3. Mallory FB, Wright JH. *Pathological Technique*. Philadelphia: W. B. Saunders, 1898 (new eds. 1901, 1904, 1908, 1911, 1915, 1918).
4. Wright JH. A case of mycetoma (Madura foot). *J Exp Med* 3:422–433, 1898.
5. Wright JH. Examples of the application of "color screens" to photomicrography. *J Bost Soc Med Sci* 3:302–307, 1899.
6. Wright JH, Brown LS. Photographs of malarial parasites. *J Bost Soc Med Sci* 3:2–3, 1899.
7. Wright JH. A case of multiple myeloma. *J Bost Soc Med Sci* 4:195–204, 1900.
8. Wright JH. A simple method of cultivating anaerobic bacteria. *J Med Sci* 5:114–116, 1900.
9. Wright JH. Eine schnelle Methode zur dauernden Aufbewahrung gefrorener Schnitte (A fast method for long-term storage of frozen section). *Centrablatt für Allgemeine Pathologie und Pathologische Anatomie* 12:634–635, 1901.
10. Wright JH, Joslin EP. Degeneration of the islands of Langerhans of the pancreas in diabetes mellitus. *J Med Res* 6:360–365, 1901.
11. Wright JH. A rapid method for the differential staining of blood films and malarial parasites. *J Med Res* 7:138–144, 1902.
12. Wright JH. Protozoa in a case of tropical ulcer (Delhi sore). *J Med Res* 10:472–482, 1903.
13. Wright JH. The biology of the microorganism of actinomycosis. *J Med Res* 134:349–404, 1905.
14. Wright JH. A method for the differential staining of blood plates. *Bost Med Surg J* 155:30–31, 1906.
15. Wright JH. The origin and nature of the blood plates. *Bost Med Surg J* 154:643–645, 1906.
16. Wright JH. Actinomycosis. In *Modern Medicine: Its Theory and Practice*. Osler W, ed. Philadelphia: Lea Brothers, 1907.
17. Wright JH. Nocardiosis, mycetoma, oidiomycosis, blastomycosis, pulmonary aspergilliosis, mycosis mucornia. In *Modern Medicine: Its Theory and Practice*. Osler W, ed. Philadelphia: Lea Brothers, 1907.
18. Wright JH, Richardson O. Treponemata (Spirochaetae) in syphilitic aortitis. Five cases, one with aneurysm. *Bost Med Surg J* 160:539–541, 1909.
19. Wright JH. Neurocytoma or neuroblastoma. A kind of tumor not generally recognized. *J Exp Med* 12:556–561, 1910.
20. Wright JH. Revised directions for making and using the Wright blood stain. *JAMA* 55:1979, 1910.
21. Wright JH. The histogenesis of the blood platelets. *J Morph* 21:263–278, 1910.
22. Wright JH, Kinnicutt R. A new method of counting platelets for clinical purposes. *JAMA* 56:1457–1459, 1911.
23. Wright JH. Non-bacterial fungus infections—the mycoses. In *Modern Medicine: Its Theory and Practice*. Osler W and McCrae T, eds. 2nd ed. Philadelphia: Lea and Febiger, 1913.
24. Wright JH, Minot GR. The viscous metamorphosis of the blood platelets. *J Exp Med* 26:395–409, 1917.
25. Wright JH. Non-bacterial fungus infections—the mycoses. In *Modern Medicine: Its Theory and Practice*. Osler W and McCrae T, eds. 3rd ed. Philadelphia: Lea and Febiger, 1925.