

Percutaneous Interspinous Spacers for the Management of Lumbar Spinal Stenosis

- Lumbar spinal stenosis is a major healthcare concern, especially given the aging population in the US and elsewhere.
- Interspinous spacers offer the possibility of relief for patients diagnosed with lumbar spinal stenosis resulting in neurogenic claudication.
- FDA approval of a percutaneous interspinous spacer provides a minimally invasive option for the treatment of these patients.

AS the US population ages, the incidence of age-related degeneration of the musculoskeletal system is increasing. The lumbar spine is one of the most affected areas in aging patients, with arthritis-related and other types of degenerative changes often leading to narrowing of the spinal canal and/or neural foramina. As a consequence, there can be compression of the nerves extending into the legs: a condition known as lumbar spinal stenosis (LSS). LSS can result in the patient having difficulty walking more than 50 feet or sitting for long without experiencing pain, due to a syndrome called neurogenic claudication, or pseudoclaudication. Neurogenic claudication is critically differentiated from vascular claudication inasmuch as it worsens, rather than improves, with ambulation. Classically, the pain or pain equivalent is relieved when the patient flexes at the waist, a phenomenon often described as the "shopping cart" sign.

According to a 2015 study, an estimated 1.2 million patients in the US are diagnosed with LSS annually, and more than 175,000 surgeries are performed, making stenosis the most common reason for spine surgery in patients 65 years or older. The prevalence of the condition is expected to balloon to 64 million people by 2025.

Interspinous spacers can be utilized to treat patients with LSS. The latest iterations of the devices are inserted percutaneously, requiring a relatively small incision and allowing patients to return home the day of their procedure. For properly chosen patients suffering from neurogenic claudication, this approach can provide meaningful relief.

Treatment Options for Lumbar Spinal Stenosis

When a patient is diagnosed with LSS, the initial treatment comprises a range of conservative approaches variably encompassing physical therapy, pain medications including opioids and nonsteroidal anti-inflammatory drugs, and epidural steroid injections. Depending on the reference, conservative approaches will not resolve the pain or the mobility issues in as many as 40% of patients. In these cases, providers and patients will generally consider more invasive options.

Decompressive laminectomy allows the surgeon to relieve pressure on the spinal cord or nerves by removing the offending elements that are causing the stenosis. The offending elements can include bone spurs, discal or ligamentous tissue compressing the neural structures. This treatment, which remains the gold standard, typically entails an open operative approach with its associated recovery.

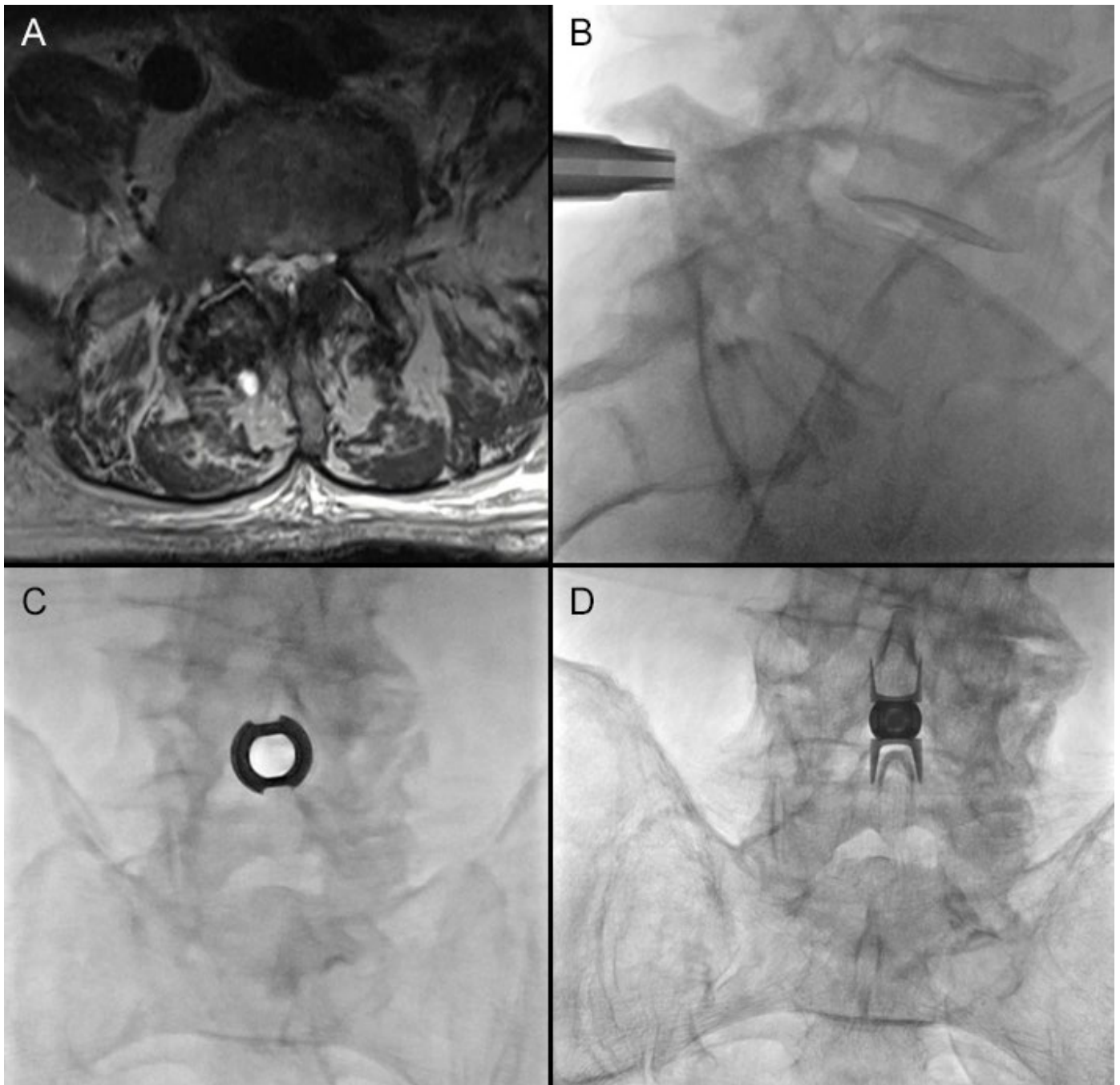


Figure 1. An elderly patient presented with neurogenic claudication. **(A)** Axial T2 weighted MRI demonstrates severe canal stenosis. **(B)** and **(C)** Intraoperative pictures demonstrate the dilator being placed percutaneously between the spinous processes followed by an AP view of the working canula. **(D)** The final picture demonstrates the fully deployed device. The patient was discharged several hours later to home.

Interspinous devices work by inserting an implant between two spinous processes to keep the respective vertebrae apart and thus relieve pressure on the nerves extending into the legs, simulating the flexed waist or the "shopping cart" sign. The dynamic vertebral fixation concept was developed along with the first interspinous implant in the 1980s. The first-generation devices could not be placed percutaneously, though, and suffered from mechanical and functional limitations.

In 2005, the FDA approved another interspinous device, known as the X-Stop, for commercial distribution in the US. A decade later, in 2015, a truly minimally invasive interspinous spacer was granted approval. This device, known as Superior, could be inserted percutaneously and thus could offer relief for patients who are not considered good surgical candidates.

Studies Demonstrate Clinical Utility of Next-Generation Interspinous Spacer

Since 2015, studies have followed patients treated with the Superion device during its noninferiority trial. A paper published in 2017 in the journal *Clinical Interventions in Aging* reported the five-year clinical outcomes and compared them to outcomes in patients who underwent decompressive laminectomy for treatment of LSS. The authors found that 84% of the patients demonstrated clinical success in at least two of the three areas in the Zurich Claudication Questionnaire (ZCQ), a self-report instrument used to measure outcomes in patients with LSS. The three areas are symptom severity, physical function and patient satisfaction. They also noted clinical success in leg and back pain. An additional study, published in *World Neurosurgery*, found comparable reoperation rates between patients treated with Superion and decompressive laminectomy.

During this period, a Mass General investigator was working with colleagues in Europe, where percutaneous interspinous tracers were already widely in use, to determine the efficacy of the devices. In a 2015 paper published in the *Journal of Vascular Interventional Radiology*, Joshua Hirsch, MD, Vice Chair of Procedural Services at Mass General, and collaborators from Azienda Ospedaliero Universitaria (A.O.U.), di Cagliari–Polo di Monserrato, Italy, and elsewhere reported three-year outcomes on eighty patients treated with commercially approved percutaneous spacers. Beyond the successful clinical parameters, this study reported on pre- and post-central canal and neural foraminal cross-sectional area changes at one-year post treatment with improvements of 15%. Through pre- and post-radiology measurements, the researchers helped to demonstrate the clinical utility of percutaneous interspinous spacers.

Scheduling

Treatment of lumbar spinal stenosis with percutaneous interspinous spacers is offered on the main campus of Massachusetts General Hospital in Boston. Consults with the Neurointerventional Spine program can be requested in Epic (Ambulatory, MGH Neurointerventional Spine) or Physician Gateway (outside the Partners network) or by calling 617-726-1767.

Further Information

For more information about use of interspinous tracers to treat lumbar spinal stenosis, please contact [Joshua Hirsch, MD](#), Department of Radiology, Massachusetts General Hospital. We would like to thank Dr. Hirsch and Nurse Practitioners Marion Gowney and Teresa Vanderboom, both also of the Department of Radiology, Massachusetts General Hospital, for their advice and assistance in preparing this article.

References

- Laurysen C, Jackson RJ, Baron JM, Tallarico RA, Lavelle WF, Deutsch H, et al. (2015). *Stand-alone interspinous spacer versus decompressive laminectomy for treatment of lumbar spinal stenosis*. *Expert Rev Med Devices* 12(6): 763-9.
- Manchikanti L, Pampati V, Hirsch JA. (2016). *Retrospective cohort study of usage patterns of epidural injections for spinal pain in the US fee-for-service Medicare population from 2000 to 2014*. *BMJ Open* 6(12): e013042.
- Marcia S, Hirsch JA, Chandra RV, Marras M, Piras E, Anselmetti GC, et al. (2015). *Midterm Clinical and Radiologic Outcomes after Percutaneous Interspinous Spacer Treatment for Neurogenic Intermittent Claudication*. *J Vasc Interv Radiol* 26(11): 1687-93 e1-2.
- Nunley PD, Patel VV, Orndorff DG, Lavelle WF, Block JE, Geisler FH. (2017). *Superion Interspinous Spacer Treatment of Moderate Spinal Stenosis: 4-Year Results*. *World Neurosurg* 104: 279-83.
- Nunley PD, Patel VV, Orndorff DG, Lavelle WF, Block JE, Geisler FH. (2017). *Five-year durability of stand-alone interspinous process decompression for lumbar spinal stenosis*. *Clin Interv Aging* 12: 1409-17.
- Parker SL, Anderson LH, Nelson T, Patel VV. (2015). *Cost-effectiveness of three treatment strategies for lumbar spinal stenosis: Conservative care, laminectomy, and the Superion interspinous spacer*. *Int J Spine Surg* 9: 28.
- Patel VV, Nunley PD, Whang PG, Haley TR, Bradley WD, Davis RP, et al. (2015). *Superion((R)) InterSpinous Spacer for treatment of moderate degenerative lumbar spinal stenosis: durable three-year results of a randomized controlled trial*. *J Pain Res* 8: 657-62.
- Patel VV, Whang PG, Haley TR, Bradley WD, Nunley PD, Davis RP, et al. (2015). *Superion interspinous process spacer for intermittent neurogenic claudication secondary to moderate lumbar spinal stenosis: two-year results from a randomized controlled FDA-IDE pivotal trial*. *Spine (Phila Pa 1976)* 40(5): 275-82.

©2019 MGH Department of Radiology

Gary Boas, Author
Raul N. Uppot, M.D., Editor

