

Endovenous Laser Therapy for Lower Extremity Venous Insufficiency

- While some varicose veins may be non-symptomatic, many are associated with itching, pain, a feeling of lower extremity heaviness, and muscle cramping; some may progress to severe chronic vascular disease, resulting in skin changes or venous ulcers.
- Percutaneous endovenous thermal ablation (EVTA), using either radiofrequency or laser energy, achieves success rates comparable to surgical stripping and is associated with faster recovery and less periprocedural morbidity.
- Endovenous laser therapy (EVLT) is performed as outpatient therapy using tumescent anesthesia under ultrasound guidance.
- Additional treatments for superficial varicosities, tributaries, and/or perforator veins, such as ambulatory phlebectomy, sclerotherapy, or EVTA of perforators, may be performed after initial ablation.

The severity of chronic venous disease ranges from spider veins (telangiectasia), which are mainly cosmetic, to non-symptomatic varicose veins to debilitating disease with symptoms of itching, pain, lower extremity heaviness, and muscle cramping. In the worst cases, venous disease can progress, resulting in edema, skin pigmentation changes, lipodermatosclerosis, and venous ulcers. Severe chronic venous disease can lead to chronic pain, disability, lower quality of life, and early retirement.

Most primary varicosities occur in the great saphenous vein (GSV), a superficial vein that runs from the ankle to the common femoral vein. They can also occur in the small saphenous vein (SSV) and in perforator veins. Spider veins can develop in reticular veins, the network of small veins parallel to the skin that drain the skin and subcutaneous tissue. These superficial veins carry approximately 10% of lower extremity venous blood; the remainder flows through deep veins.

Several options are available for the treatment of lower extremity venous insufficiency, including compression stockings, which are used when patients cannot undergo more radical therapies (such as pregnant patients), sclerotherapy, image-guided thermal ablation, chemical ablation and surgical venous stripping.

Endovenous Thermal Ablation

Endovascular thermal ablation (EVTA) is an effective treatment for varicose veins with long-term results equivalent to surgical stripping, which historically has been the treatment of choice. The thermal effect can be achieved either by radiofrequency waves (radiofrequency ablation, RFA) or by laser energy (endovenous laser therapy, EVLT). The latter is described here.

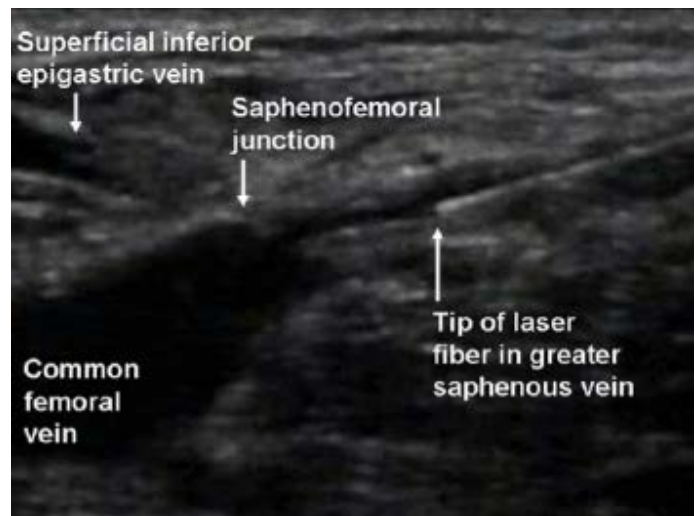


Figure 1. Laser ablation technique: Under US guidance, and with the use of local anesthetic, the GSV is punctured and a 5-F introducer sheath is placed into it over a guide wire, and advanced past the SFJ into the femoral vein. This position is confirmed by US imaging. A vascular sheath is then inserted over the wire and positioned 2 cm caudal to the SFJ and a laser fiber is placed through the sheath at this level.

EVLT is performed as an outpatient treatment using tumescent anesthesia. Before the ablation, duplex ultrasound is performed to map the incompetent veins. To maximize visualization of the veins, this procedure is performed in the anti-Trendelenburg (feet down) position. The skin is marked to show the incompetent portion of the vein, starting at the saphenofemoral junction (SFJ) for the great saphenous vein (GSV) or the saphenopopliteal junction (SPJ) for the small saphenous vein (SSV). After the veins have been mapped, an entry point below the level of reflux is selected, or a point proximal to where the vein is too small to access.

Under local anesthesia at the site of needle placement, the vein is punctured with a 16- or 18-gauge needle under ultrasound guidance. A 5-French introducer sheath is placed over a guide wire into the GSV or SSV, below the saphenous junctions with femoral (Figure 1) and popliteal veins, respectively. Under tumescent anesthesia with lidocaine, the laser tip is advanced through the varicosity. Thermal energy is delivered as the laser is withdrawn at a rate of 10–12 cm/minute to ablate the vein.

After completion of the procedure, ultrasound of the SFJ is performed to rule out deep vein thrombosis (DVT). Compression stockings are then placed on the treated extremity. Patients are sent home after a brief recovery period and instructed to walk immediately as well as wear compression stockings for two weeks. After this time, patients are routinely screened by ultrasound to assess the results of treatment. Recanalization is possible, especially if patients have not complied with instructions to wear compression stockings.

Clinical Outcome

Success rates for treatment of reflux in the GSV have been reported to be >90%. Adverse effects may include paresthesia, pain, ecchymosis, hematoma, and phlebitis and are self-limiting. Rarely, patients may develop deep vein thrombosis or experience superficial laser-related burns. Recovery is rapid.

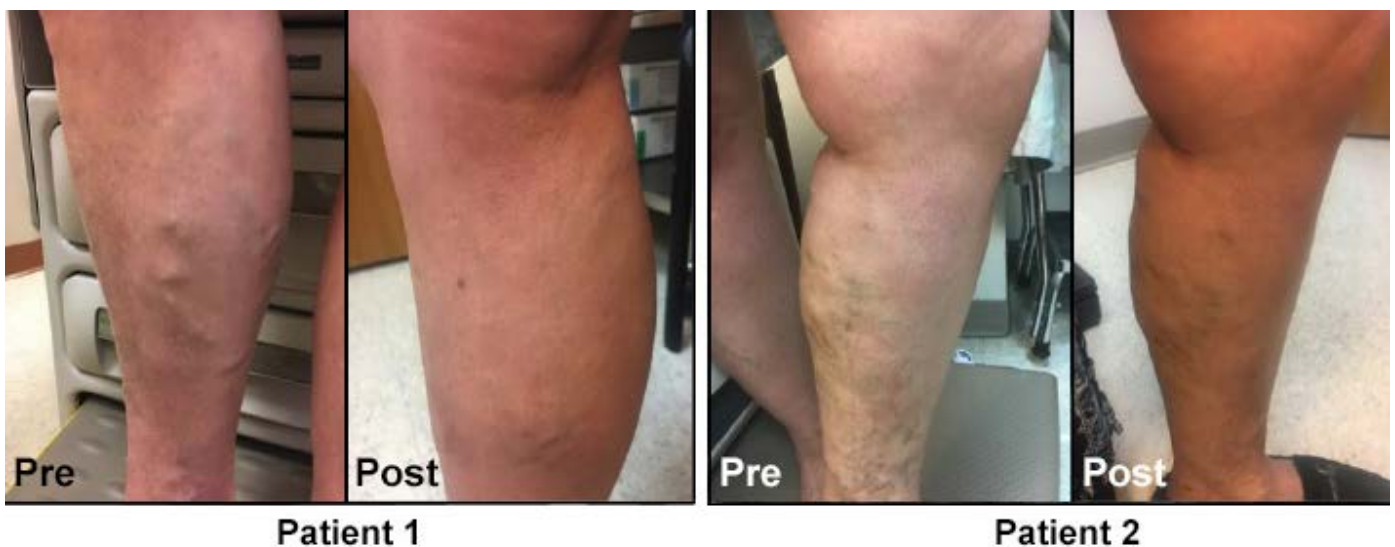


Figure 2. Pre- and post- treatment images of varicose veins patients.

Additional Treatments

After successful elimination of reflux in larger veins (Figure 2), there may be a need to perform additional treatments for superficial varicosities, tributaries, and/or perforator veins. Treatment options include ambulatory phlebectomy, sclerotherapy, or EVLT of perforators. These treatments are typically performed in a subsequent procedure, but they can be performed on the same day.

Contraindications

EVLT is not recommended for patients who are pregnant or breastfeeding, have an obstructed deep venous system inadequate to support circulation, allergy to lidocaine, severe uncorrectable coagulopathy or hyper coagulability, inability to ambulate after the procedure, sciatic vein reflux, or tortuous veins that do not allow the passage of the endovenous device.

Scheduling

Ultrasound-guided EVLT is performed on the main campus of Massachusetts General Hospital in Boston, MA in the Division of Interventional Radiology and the Division of Vascular and Endovascular Surgery. It is also performed at the Vascular Center at Mass General Waltham, MA and at the Surgery Center at Mass General/North Shore Center for Outpatient Care in Danvers, MA. Appointments can be made through Epic (inside the Partners network) or [Physician Gateway](#) (outside the Partners network) or by calling 617-643-4723.

Further Information

For further information on the treatment of patients with varicosities and other manifestations of chronic venous disease, please contact [Gloria Salazar, MD](#), Division of Interventional Radiology, Department of Radiology, Massachusetts General Hospital, at 617-643-4723.

We would like to thank Gloria Salazar, MD, for her advice and assistance in preparing this article.

References

ArnoGloviczki, Comerota, Dalsing, et al., 2011, Hamdan, Livingston and Lynn, 2013, Huang and Gloviczki, 2016, White and Ryjewski, 2005

Gloviczki P, Comerota AJ, Dalsing MC, et al. (2011). *The care of patients with varicose veins and associated chronic venous diseases: clinical practice guidelines of the Society for Vascular Surgery and the American Venous Forum*. *J Vasc Surg* **53**:2S-48S

Hamdan A, Livingston EH and Lynn C (2013). *JAMA patient page. Treatment of varicose veins*. *JAMA* **309**:1306

Huang Y and Gloviczki P (2016). *Relationships between duplex findings and quality of life in long-term follow-up of patients treated for chronic venous disease*. *Phlebology* **31**:88-98

White JV and Ryjewski C (2005). *Chronic venous insufficiency*. *Perspect Vasc Surg Endovasc Ther* **17**:319-27

©2017 MGH Department of Radiology

Janet Cochrane Miller, D. Phil., Co-Author

Raul N. Uppot, M.D., Editor

